



Case Report

Correction of Unilateral Posterior Crossbite with U-MARPE

Jonathan Dzingle¹ , Shivam Mehta² , Po-Jung Chen² , Sumit Yadav² 

¹Private Practice, Michigan, United States

²Division of Orthodontics, University of Connecticut Health Center, School of Dental Medicine, Farmington, Connecticut, United States

Cite this article as: Dzingle J, Mehta S, Chen PJ, Yadav S. Correction of Unilateral Posterior Crossbite with U-MARPE. Turk J Orthod 2020; 33(3): 192-6.

ABSTRACT

Unilateral posterior crossbite typically presents as a narrow maxillary arch and a broad mandibular arch on the side of the crossbite. Unwanted overexpansion and iatrogenic crossbite may develop as side effects if conventional rapid maxillary expansion is done in such cases. Thus, unilateral expansion of the maxilla with unilateral posterior crossbite can help us avoid these side effects and improve the transverse relationship between the maxillary and mandibular posterior dentition on the affected side only. In this case report, we describe a mini-implant-supported unilateral expansion of the maxillary arch in a patient with a unilateral posterior crossbite.

Keywords: Asymmetry, mini-implant, unilateral crossbite, unilateral expansion

Main points:

- Unilateral posterior crossbite can be corrected with a modified design of mini-implant-assisted rapid palatal expander (MARPE)—the U-MARPE—without undesirable movement on the unaffected side.
- U-MARPE facilitates better control over force distribution than a regular expander and thus more efficient correction of the unilateral posterior crossbite.
- Comprehensive diagnosis and treatment planning can lead to targeted orthodontic mechanotherapy and esthetic results.

INTRODUCTION

Unilateral posterior crossbite is usually characterized by a narrow maxillary arch and broad mandibular arch on the crossbite side (1). These patients are treated with maxillary expansion to correct the transverse discrepancy, but ideally, the expansion should be done only for the side that is in crossbite (2). A posterior crossbite is a form of discrepancy in the transverse dimension between the maxillary and mandibular arches with a prevalence of 8%–23% (3). Both unilateral and bilateral posterior crossbite are equally prevalent (4-6). The etiology is multifactorial, which influences dentofacial growth and may lead to the development of posterior crossbite (5).

The treatment of posterior crossbite often involves maxillary arch expansion to improve the relationship between the maxillary arch and mandibular arch in the transverse dimension. However, when bilateral rapid palatal expansion (RPE) is done in a patient with unilateral posterior crossbite, it results in overexpansion and iatrogenic creation of the crossbite on the side that had normal transverse relationship before treatment (7, 8). In addition, the treatment of iatrogenic crossbite results in increased treatment time and increased discomfort for the patient. Thus, unilateral expansion of the maxilla in patients with unilateral posterior crossbite can help us avoid these side effects and can be used to correct the transverse relationship between the maxillary and mandibular posterior dentition on the affected side only. In this case report, we describe a modified mini-implant-assisted rapid palatal expander (MARPE) design for unilateral expansion (U-MARPE) of the maxillary arch in order to correct the unilateral posterior crossbite.

CASE PRESENTATION

Diagnosis

A 19-year-old Hispanic male presented to the department of Orthodontics with the chief complaint that he was not pleased with his bite. The patient reported food allergy; however, no contraindication to orthodontic treatment was noted. Clinical examination showed a straight profile (Figure 1). Maxillary dental midline and facial midline were coincident, and there was deviation of the mandibular dental midline to the left by 1 mm. He had Class III canine and Class I molar relationship bilaterally (Figure 1). The teeth from the maxillary left canine to the maxillary left second molar were in a crossbite, and no discrepancy was noted between centric occlusion and centric relation. Crowding of 2 mm and 1.5 mm in the maxillary arch and the mandibular arch, respectively, was noted. There were no signs or symptoms of temporomandibular joint dysfunction. No significant pathology was found in the panoramic radiograph (Figure 2). The lateral cephalogram showed a Class I maxillomandibular relationship with Class III tendency and normal mandibular plane angle (Figure 3). In summary, the patient was diagnosed with skeletal and dental Class I malocclusion.

Treatment Objectives

The treatment objectives were to (1) achieve Class I canine relationship and maintain Class I molar relationship bilaterally, (2)

establish a normal buccal overjet and overbite relationship, and (3) maintain the facial profile.

Treatment Plan and Alternatives

Different treatment plans were taken into consideration and explained to the patient. The treatment plan chosen for this patient was non-extraction and non-surgical treatment with U-MARPE for maxillary expansion to correct the posterior crossbite. After discussing this option with the patient, a non-extraction treatment with U-MARPE was adopted.

Another treatment option was non-extraction orthodontic treatment combined with surgically assisted rapid maxillary expansion (SARME). This approach can correct the transverse skeletal discrepancy; however, the patient did not accept this plan because of the added financial burden, having to undergo a surgical procedure, and the complications.

Treatment Progress

The different treatment options and the objectives of the orthodontic treatment were described to the patient in detail, and the written informed consent form was obtained. The U-MARPE appliance was delivered with 2 mini-implants (2×8 mm, 3M Unitek, St. Paul, MN) on the right palatine bone and bands on maxillary left first molar and first premolar (Figure 4). The activation was started with one turn per day for 2 weeks. The crossbite on the left side was corrected after expansion. The expander was stabilized for 5 months after expansion.

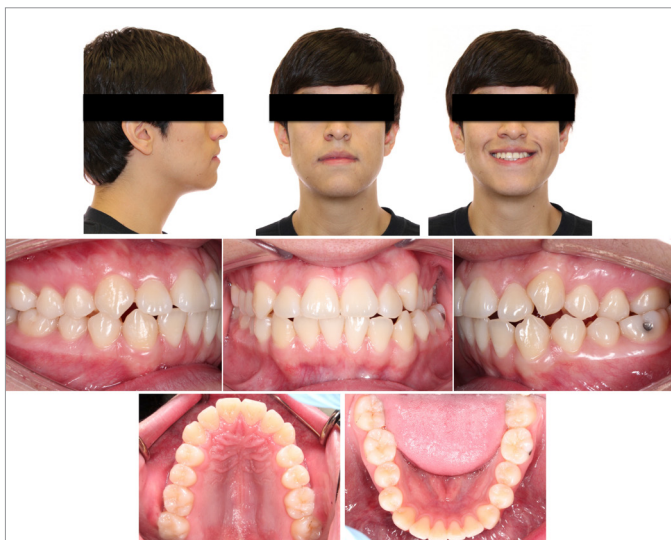


Figure 1. Pretreatment facial and intraoral photographs

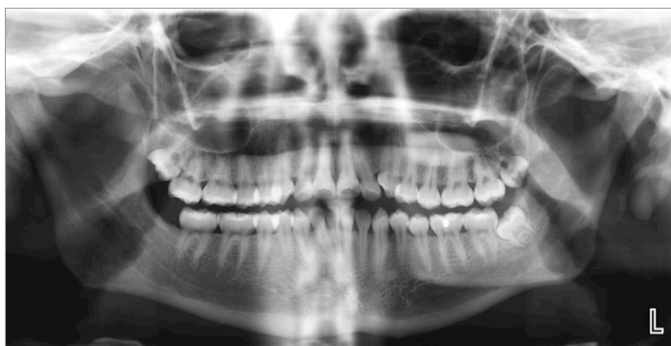

Figure 2. Pretreatment panoramic radiograph

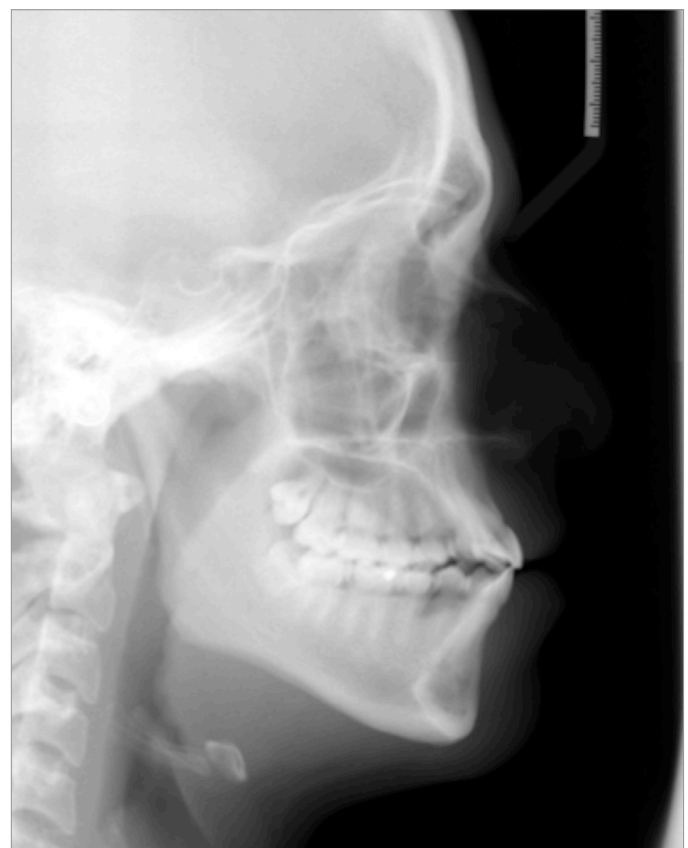

Figure 3. Pretreatment lateral cephalometric radiograph

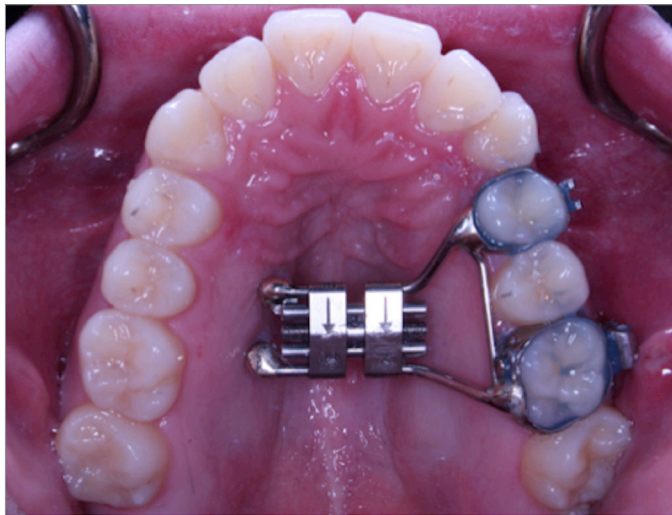


Figure 4. U-MARPE appliance applied with 2 mini-implants and bands on the maxillary first premolar and maxillary first molar

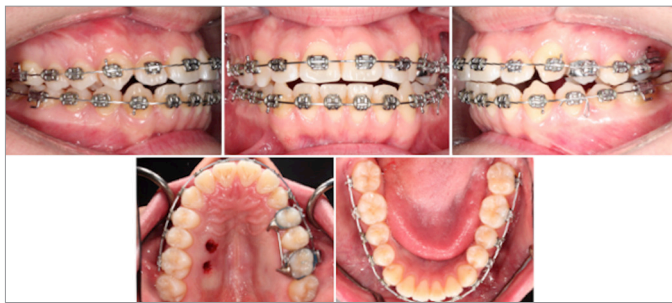

Figure 5. Removed U-MARPE and the bonded pre-adjusted edgewise appliance 0.022x0.028.

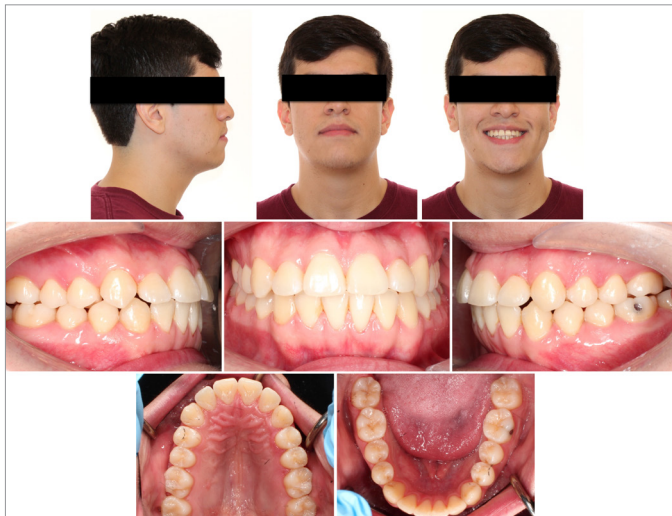

Figure 6. Posttreatment facial and intraoral photographs

The U-MARPE was removed after 6 months of stabilization. Bonding was done using the preadjusted edgewise appliance with 0.022x0.028-in slot size (Figure 5). The leveling and alignment was achieved by beginning with 0.016-in nickel-titanium and building up to 0.019x0.025-in stainless steel in 6 months.

Braided stainless steel archwires (0.017x0.025-in) were used for finishing. The orthodontic treatment was completed in 24

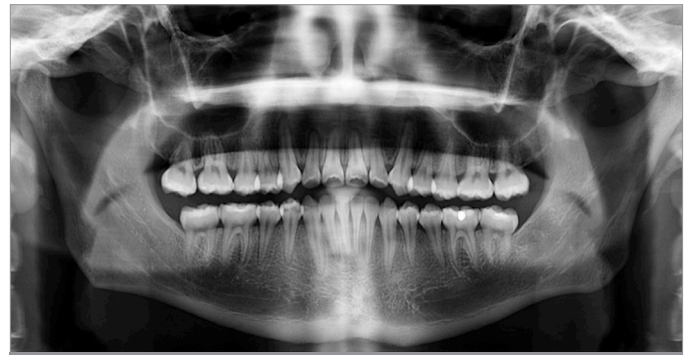

Figure 7. Posttreatment panoramic radiograph

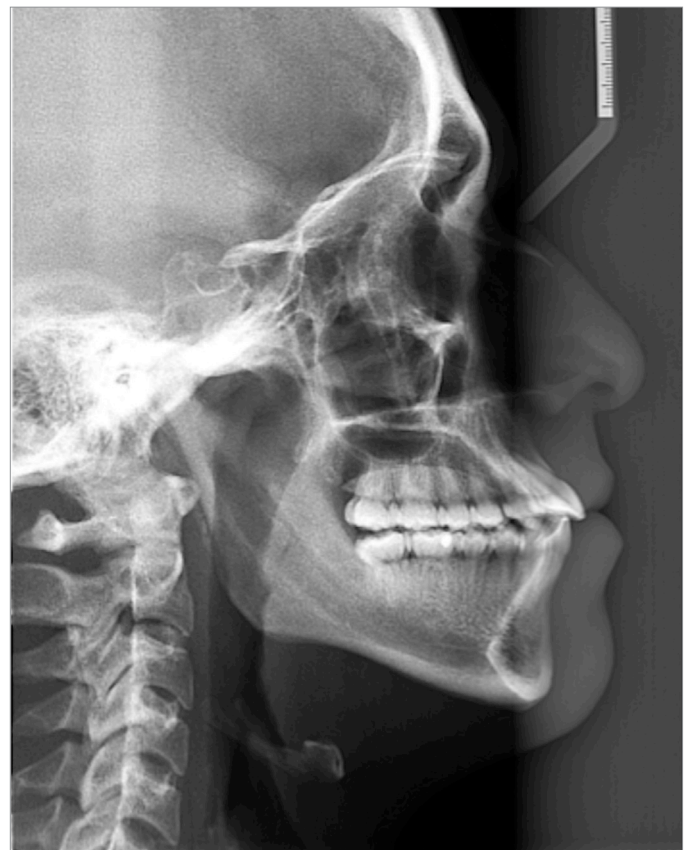

Figure 8. Posttreatment lateral cephalometric radiograph

months. For retention, upper Essix clear retainer and lower lingual fixed retainer were used.

Treatment Results

The patient was very satisfied with the treatment result and exhibited a pleasant smile at the end of treatment (Figure 6). The palatal crossbite was corrected, and the arches were well aligned with ideal overbite and overjet. The dental midlines were coincident in both arches.

Good root parallelism was observed after treatment (Figure 7). The overall superimposition showed mild mandibular growth, whereas regional superimposition showed mild extrusion of mandibular incisors and mandibular first molars (Figures 8 and 9). The occlusogram showed the asymmetric expansion of the maxillary arch (Figure 10).

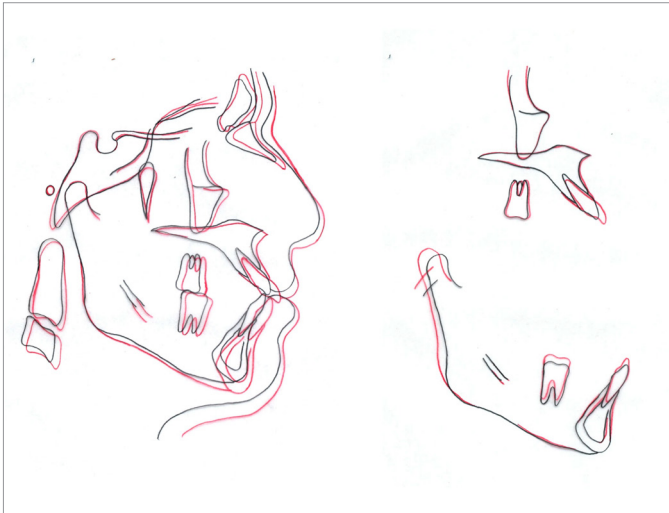


Figure 9. Superimposition showing pretreatment (black) and posttreatment (red) cephalograms



Figure 10. Superimposition of the pretreatment (blue) and posttreatment (orange) maxillary arch occlusograms

DISCUSSION

In a true unilateral posterior crossbite, it is very important that the appliance design and load system are such that unilateral expansion occurs only on the affected side and not on the side without crossbite. In our patient, U-MARPE was used to correct unilateral crossbite without undesirable movement on the unaffected side. The occlusion of the side without crossbite was maintained very well after the expansion was done. Instead of using conventional RPE and Surgically Assisted Rapid Palatal Expansion (SARPE), the U-MARPE demonstrated a decent amount of expansion without additional surgery in a 19-year-old patient.

The objective of the U-MARPE was to allow expansion of the crossbite side without clinical side effects on the opposite side. Use of the conventional RPE procedure to correct unilateral posterior crossbite needs an asymmetric relapse after bilateral expansion. To avoid this undesirable movement, previous studies support the use of an RPE with an acrylic plate having locked mechanics on the side without crossbite to produce asymmet-

ric orthopedic and orthodontic effects (2, 9). Appliances such as an asymmetric maxillary expansion (AMEX) appliance have also been used for the correction of unilateral crossbite (10). It has been reported to show increased expansion on the crossbite side and relatively less expansion on the side without crossbite. However, the activation of the appliance is done extra-orally, which requires removal and recementation of the appliance and, thus, increase the clinical chair time. In addition, some side effects might be observed on the maxillary and mandibular premolars and molars on the side without crossbite because they are used as anchorage units. In our design, the activation of the screw was done intraorally by the patient and does not use mandibular teeth as an anchor unit and therefore does not lead to expansion of the mandibular teeth. However, the results of the AMEX appliance imply that it can be used as an alternative in patients who do not wish to use temporary anchorage devices (TADs) (10).

As unilateral expansion has been reported with SARME in adults, it was an alternative treatment plan for our patient (11). The results from the study by Karabiber et al. (11) showed that there was more expansion on the osteotomy side with unilateral SARME, which helped in the correction of the transverse discrepancy. Thus, unilateral SARME is an effective technique for the correction of unilateral crossbite. However, they found that there were no significant skeletal changes except for apertura piriformis (11). In addition, the SARME technique requires the patient to undergo surgery under general anesthesia and adds supplementary financial cost to the treatment. Complications like epistaxis, postoperative pain, asymmetric expansion, or inadequate expansion have been reported with SARME (12). Unilateral expansion with the U-MARPE design enabled us to correct the transverse discrepancy without surgery. The design of the U-MARPE appliance was such that the expansion force was felt by the TADs on the side without crossbite (right side) and the molars and premolars on the crossbite side (left side). This design provided better control over the force distribution than a regular expander. This enabled us to expand the molars and premolars on the left side without affecting the right side and get results comparable to those shown by unilateral SARME (11).

In the U-MARPE design, we used 2 palatal implants on the side without crossbite, and the appliance was cemented on the TADs. One advantage of using palatal TADs is their high success rate (13). The advantage of U-MARPE is that it can be delivered in the clinic under local anesthesia. Previous studies have reviewed that the results obtained with MARPE are stable (14, 15). A clinical study stated that MARPE is a stable treatment option for expansion of maxillary arch and showed that suture separation was achieved in 86.96% of those patients (15). However, this is a modified MARPE design, and further research should be done to evaluate the skeletal and dental effects of the U-MARPE design.

During expansion with the MARPE appliance, the TADs on both the sides of the mid-palatal suture apply force from the expansion screw through the palatal bone on either side of the suture, leading to the opening of the mid-palatal suture. However, in the U-MARPE design, the TADs are inserted on only one side of the

mid-palatal suture, and thus, the effects could be different than MARPE. Achieving a pure skeletal expansion was not the aim in this case, as U-MARPE will lead to expansion on both sides of the maxilla and side effects of creating a crossbite on the normal side. Rather, the objective of the U-MARPE design was to get clinical correction of the crossbite efficiently without expansion on the normal side. We believe the result obtained in our case was a combination of skeletal and dental expansion on the crossbite side. However, we did not record an occlusal radiograph of the patient after expansion in order to prevent additional radiation. However, further studies with radiographs before and after U-MARPE may help in understanding the amount of dental and skeletal expansion achieved with U-MARPE.

Thus, in this case report, we showed a case with modified MARPE design, U-MARPE, for the efficient correction of unilateral crossbite.

CONCLUSION

This case demonstrates that the use of MARPE is an effective approach to correct unilateral crossbite without causing side effects and undesirable movement on the side without crossbite.

Informed Consent: Written informed consent was obtained from the patients who agreed to take part in the study.

Peer-review: Externally peer-reviewed.

Author Contributions: Supervision – J.D., S.M., P.J.C., S.Y.; Design – J.D., S.M., P.J.C., S.Y.; Supervision – J.D., S.M., P.J.C., S.Y.; Resources – J.D., S.M., P.J.C., S.Y.; Materials – J.D., S.M., P.J.C., S.Y.; Data Collection and/or Processing – J.D., S.M., P.J.C., S.Y.; Analysis and/or Interpretation – J.D., S.M., P.J.C., S.Y.; Literature Search – J.D., S.M., P.J.C., S.Y.; Writing Manuscript – J.D., S.M., P.J.C., S.Y.; Critical Review – J.D., S.M., P.J.C., S.Y.

Conflict of Interest: The authors have no conflict of interest to declare.

Financial Disclosure: The authors declared that this study has received no financial support.

REFERENCES

1. Thilander B, Lennartsson B. A study of children with unilateral posterior crossbite, treated and untreated, in the deciduous dentition--occlusal and skeletal characteristics of significance in predicting the long-term outcome. *J Ofac Orthop* 2002; 63: 371-83. [\[Crossref\]](#)
2. Marshall SD, Southard KA, Southard TE. Early transverse treatment. *Semin Orthod* 2005; 11: 130-39. [\[Crossref\]](#)
3. Kutin G, Hawes RR. Posterior cross-bites in the deciduous and mixed dentitions. *Am J Orthod* 1969; 56: 491-504. [\[Crossref\]](#)
4. Thilander B, Myrberg N. The prevalence of malocclusion in Swedish schoolchildren. *Scand J Dent Res* 1973; 81: 12-21. [\[Crossref\]](#)
5. Dimberg L, Lennartsson B, Anrup K, Bondemark L. Prevalence and change of malocclusions from primary to early permanent dentition: a longitudinal study. *Angle Orthod* 2015; 85: 728-34. [\[Crossref\]](#)
6. Fontaine-Sylvestre C, Roy A, Rizkallah J, Dabbagh B, Ferraz Dos Santos B. Prevalence of malocclusion in Canadian children with autism spectrum disorder. *Am J Orthod Dentofacial Orthop* 2017; 152: 38-41. [\[Crossref\]](#)
7. Thilander B, Lennartsson B. A study of children with unilateral posterior crossbite, treated and untreated, in the deciduous dentition--occlusal and skeletal characteristics of significance in predicting the long-term outcome. *J Ofac Orthop* 2002; 63: 371-83. [\[Crossref\]](#)
8. Agostino P, Ugolini A, Signori A, Silvestrini-Biavati A, Harrison JE, Riley P. Orthodontic treatment for posterior crossbites. *Cochrane Database Syst Rev* 2014; 8: CD000979. [\[Crossref\]](#)
9. Ileri Z, Basciftci FA. Asymmetric rapid maxillary expansion in true unilateral crossbite malocclusion: A prospective controlled clinical study. *Angle Orthod* 2015; 85: 245-52. [\[Crossref\]](#)
10. Toroglu MS, Uzel E, Kayalioglu M, Uzel I. Asymmetric maxillary expansion (AMEX) appliance for treatment of true unilateral posterior crossbite. *Am J Orthod Dentofacial Orthop* 2002; 122: 164-73. [\[Crossref\]](#)
11. Karabiber G, Yilmaz HN, Nevzatoğlu Ş, Uğurlu F, Akdoğan T. Three-dimensional evaluation of surgically assisted asymmetric rapid maxillary expansion. *Am J Orthod Dentofacial Orthop* 2019; 155: 620-31. [\[Crossref\]](#)
12. Carvalho PHA, Moura LB, Trento GS, Holzinger D, Gabrielli MAC, Gabrielli MFR, et al. Surgically assisted rapid maxillary expansion: A systematic review of complications. *Int J Oral Maxillofac Surg* 2020; 49: 325-32. [\[Crossref\]](#)
13. Crismani AG, Bernhart T, Schwarz K, Celar AG, Bantleon HP, Watzek G. Ninety percent success in palatal implants loaded 1 week after placement: a clinical evaluation by resonance frequency analysis. *Clin Oral Implants Res* 2006; 17: 445-50. [\[Crossref\]](#)
14. Lim HM, Park YC, Lee KJ, Kim KH, Choi YJ. Stability of dental, alveolar, and skeletal changes after miniscrew-assisted rapid palatal expansion. *Korean J Orthod* 2017; 47: 313-22. [\[Crossref\]](#)
15. Choi SH, Shi KK, Cha JY, Park YC, Lee KJ. Nonsurgical miniscrew-assisted rapid maxillary expansion results in acceptable stability in young adults. *Angle Orthod* 2016; 86: 713-20 [\[Crossref\]](#)